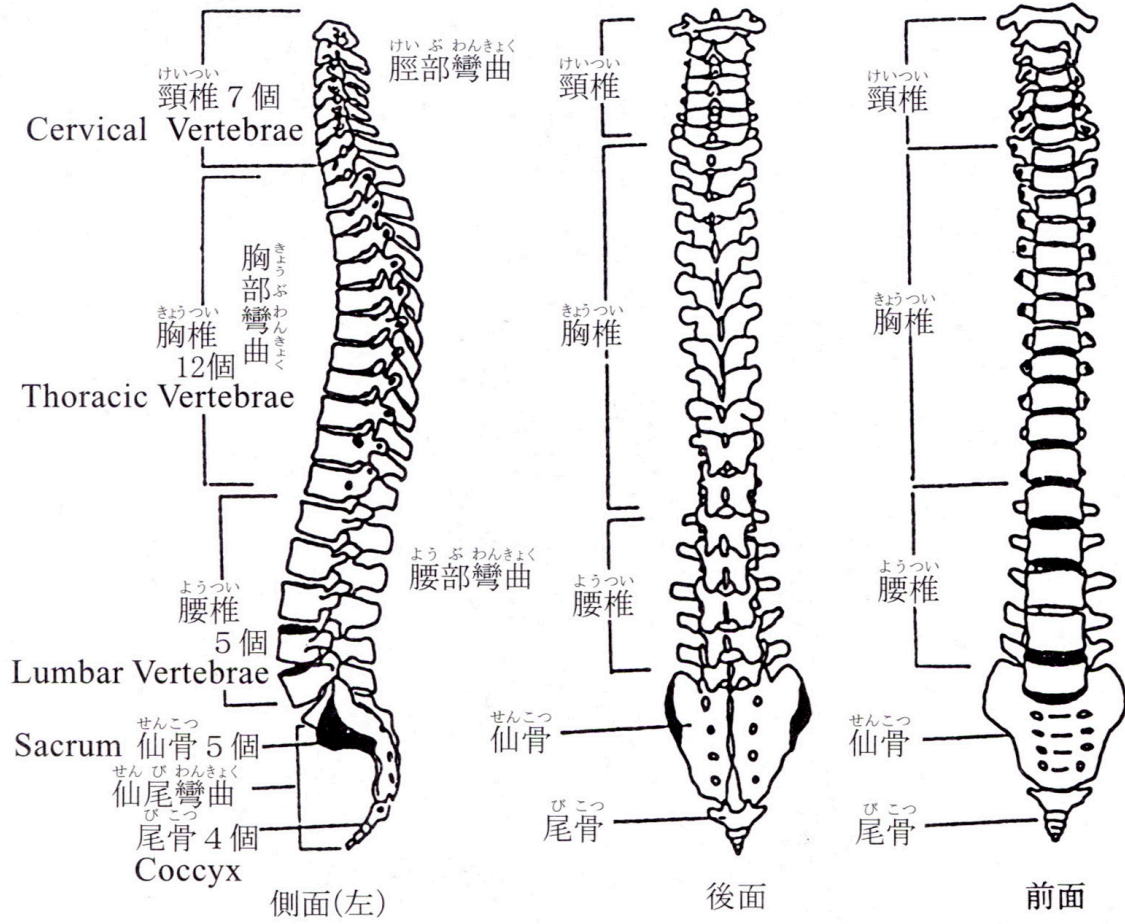
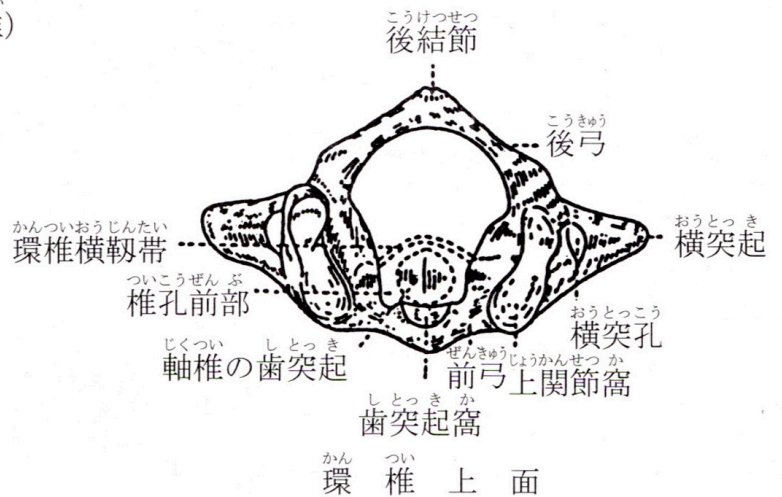
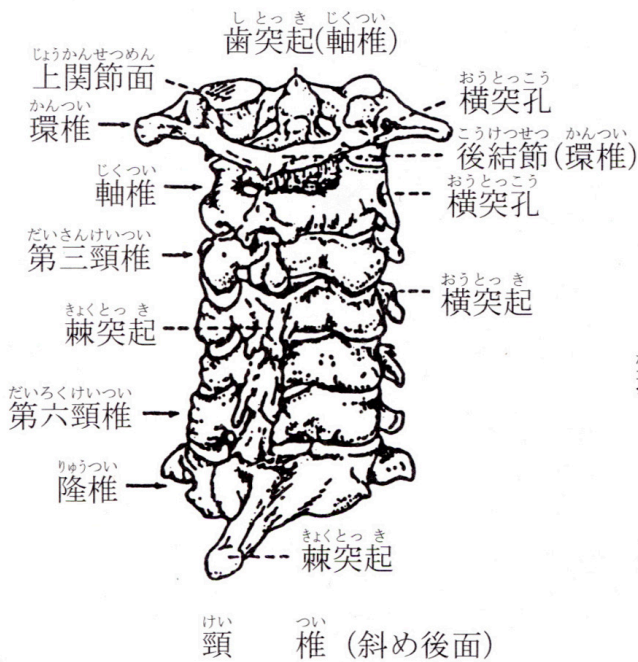


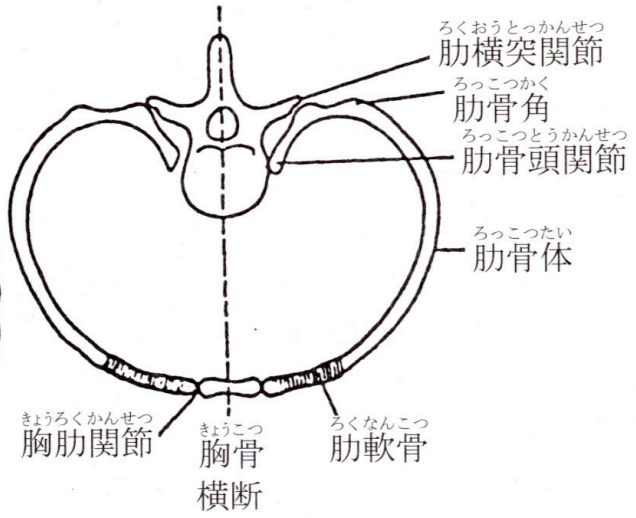
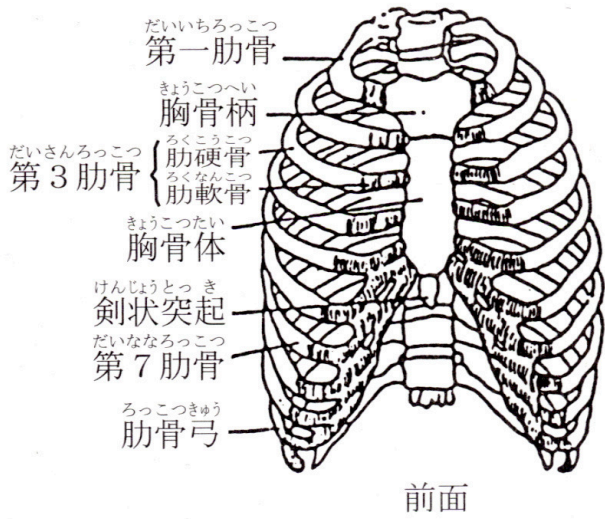
脊 柱



せき 脊 ちゆう 柱 (黒ヌリ部分は関節面)



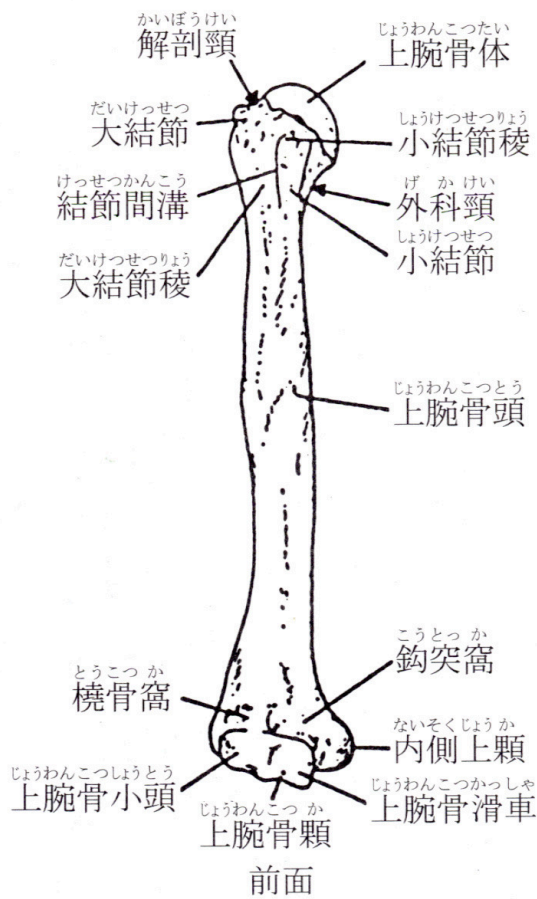
胸骨及び上肢骨



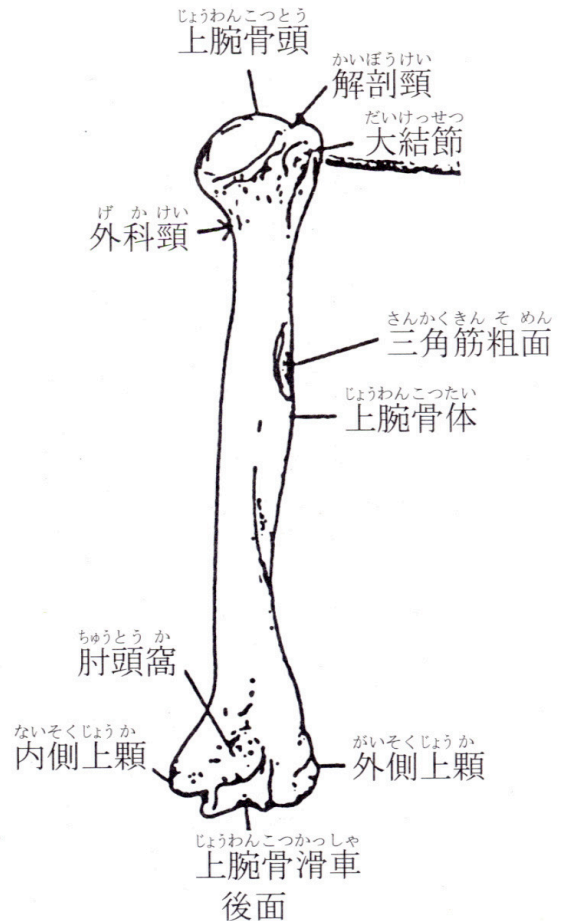
前面

横断

胸 郭

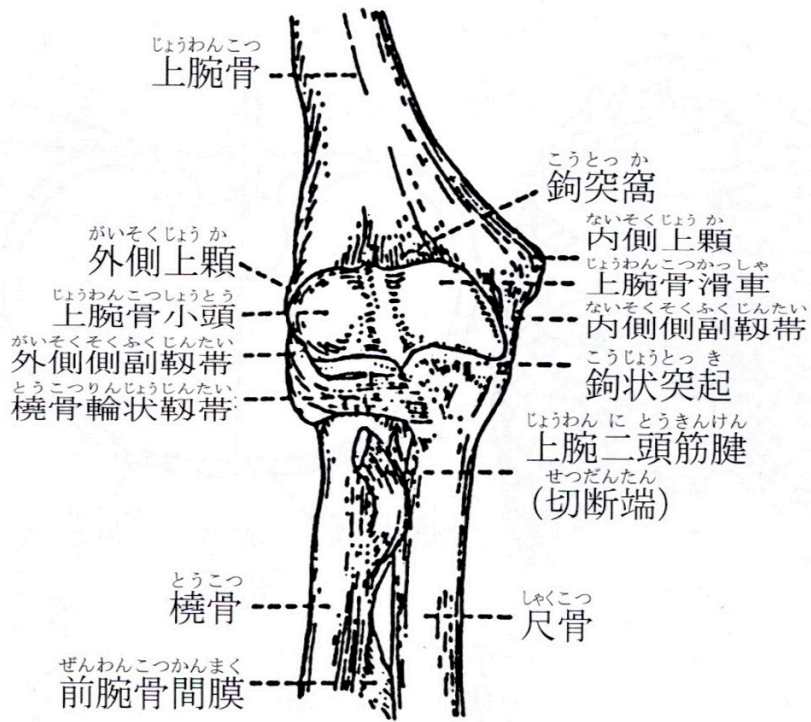


前面

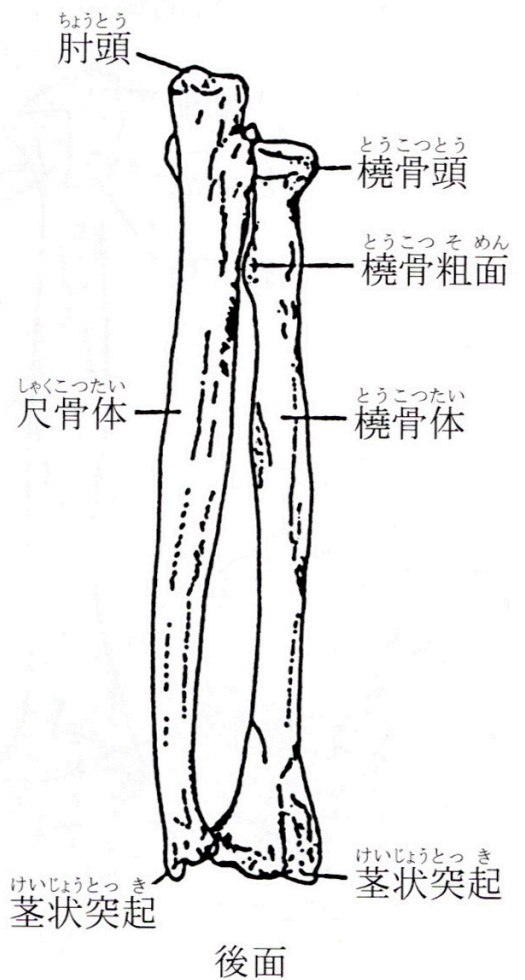
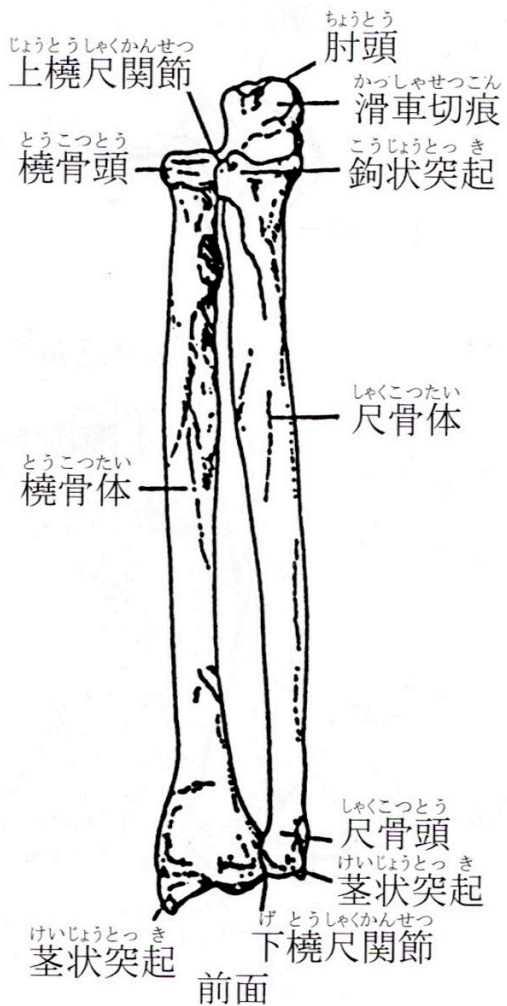


後面

上 腕 骨 (右)



肘 関 節 (右掌側面)



前 腕 骨 (右)